

Computerized Implantology for the Irradiated Patient

Andrew Horowitz, DMD, MD,* Gary Orentlicher, DMD,† and
Douglas Goldsmith, DDS‡

Reconstruction of the irradiated head and neck cancer patient continues to be a challenge. Conventional prosthodontics can be very unpredictable and difficult in these patients. Implant-supported fixed prostheses are good alternatives. It is well-accepted that maxillofacial surgery for the irradiated head and neck cancer patients should be performed in an atraumatic fashion to minimize postoperative complications. We propose the use of computer generated surgical guides and flapless surgery for the placement of dental implants in the irradiated head and neck cancer patient. With these techniques, implants can be placed in an atraumatic, predictable, and accurate manner, according to a prosthetically driven treatment plan.

© 2009 American Association of Oral and Maxillofacial Surgeons
J Oral Maxillofac Surg 67:619-623, 2009

Reconstruction in head and neck cancer patients continues to be a surgical, reconstructive, and prosthetic challenge. The ablative nature of the surgery required to treat these patients leads to significant problems with esthetics, deglutition, mastication, and speech.¹ As a result of the disease, these patients often require adjuvant radiotherapy, which subsequently may lead to further side effects such as xerostomia, mucositis, ageusia, dysphagia, odynophagia, dental caries, soft tissue necrosis, and osteonecrosis.^{2,3} These issues may lead to difficulty maintaining adequate nutritional status. Mekhail et al⁴ have shown adequate nutritional status to be an important prognostic factor.

It has been estimated that over 50% of head and neck cancer patients are malnourished.⁵ This is a result not only of the disease but also its treatment. Conventional removable prostheses may help contribute to the maintenance of adequate nutritional stores.

However, the mucosa in these patients is more likely to experience tissue breakdown. This is due in part to xerostomia and endothelial changes, which result in decreased blood flow.⁶ As head and neck cancer patients recover, it is important for them to maintain and optimize their nutritional intake. An implant-supported fixed prosthesis is a good alternative for these patients.

Unfortunately, because of the hypovascular, hypoxic, and hypocellular changes in irradiated tissues, as described by Marx,⁷ these patients are at increased risk for the development of osteoradionecrosis (ORN). In addition, any oral and maxillofacial surgery should be performed as atraumatically as possible.⁷ Computer-generated surgical guides for flapless surgery allow the surgeon to provide these patients with optimal positioning of implants, according to a restoratively driven treatment plan, with as minimal surgical trauma to the bone and associated soft tissues as possible.

We present a case of a patient diagnosed with squamous cell carcinoma of the tongue treated with radiation therapy who underwent surgical placement of dental implants. The implants were placed by use of a computer-generated surgical guide and flapless surgery.

Report of a Case

A 63-year-old woman presented to our office in 2005 for the removal of nonrestorable teeth and possible placement of dental implants (Fig 1). She had a history of hypothyroidism, and a T1 N1 M0 squamous cell carcinoma of the lateral tongue. In February 2001 she underwent a right partial glossectomy and a right

*Assistant Clinical Professor, Columbia University, College of Dental Medicine, New York, NY; Assistant Attending, New York Presbyterian Hospital, New York, NY; Associate Attending, White Plains Hospital, White Plains, NY; Private Practice, Scarsdale, NY.

†Section Chief, Division of Oral and Maxillofacial Surgery, White Plains Hospital, White Plains, NY; Private Practice, Scarsdale, NY.

‡Chief Emeritus, Division of Oral and Maxillofacial Surgery, White Plains Hospital, White Plains, NY; Private Practice, Scarsdale, NY.

Address correspondence and reprint requests to Dr Horowitz: New York Oral, Maxillofacial, and Implant Surgery, PC, 495 Central Park Ave, Suite 201, Scarsdale, NY 10583; e-mail: ahorowitz@oralsurgeryny.com

© 2009 American Association of Oral and Maxillofacial Surgeons
0278-2391/09/6703-0024\$36.00/0
doi:10.1016/j.joms.2008.09.024

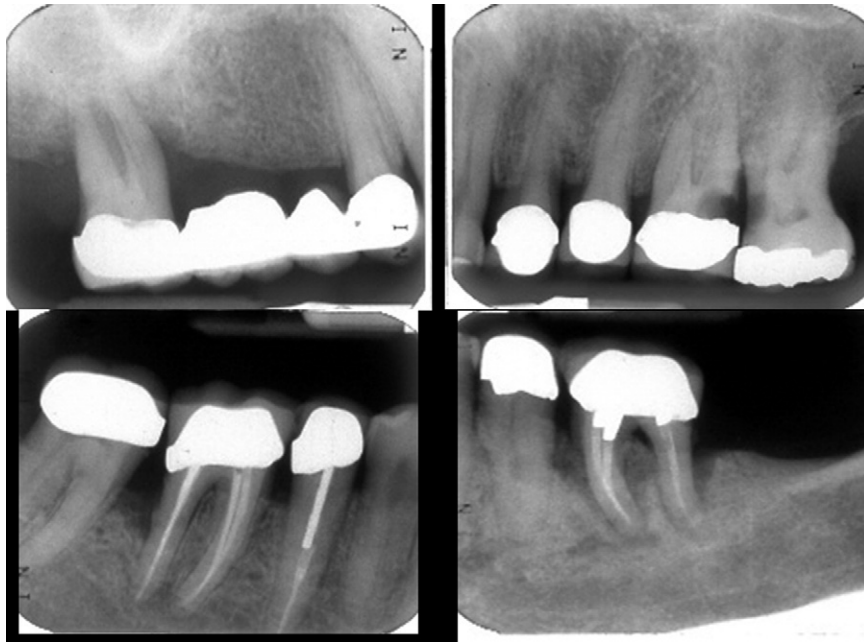


FIGURE 1. Preoperative periapical radiographs of nonrestorable teeth.

Horowitz, Orentlicher, and Goldsmith. Computerized Implantology for Irradiated Patient. J Oral Maxillofac Surg 2009.

supraomohyoid neck dissection. Postoperatively, she underwent radiation therapy with a total cumulative dose of 6,300 cGy. As a result of the radiation, prominent mucositis and esophagitis developed, requiring narcotics for pain relief. Significant xerostomia subsequently developed, which led to dental caries.

Prior to treatment, options and their associated risks were reviewed with the patient. The options that were discussed included no replacement, removable partial dentures, or an implant-supported fixed prosthesis. Assuming that her postoperative course was uneventful, the patient desired to have an implant-supported fixed prosthesis.

Because of the level of radiation the patient received, hyperbaric oxygen (HBO) therapy was recommended before the extractions. A 20/10 HBO protocol was planned for the patient: after 20 preoperative "dives," the decayed teeth were extracted in an atraumatic fashion, followed by 10 postoperative dives.⁸

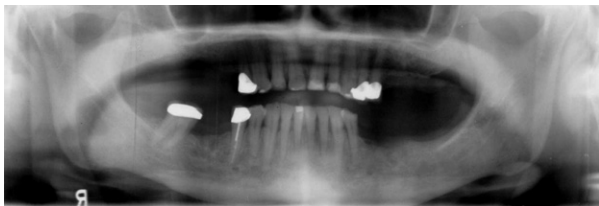

FIGURE 2. Panoramic radiograph 6 months after tooth extractions. No evidence of pathology was noted.

Horowitz, Orentlicher, and Goldsmith. Computerized Implantology for Irradiated Patient. J Oral Maxillofac Surg 2009.

Each dive consisted of 90 minutes in an HBO chamber at 100% oxygen in 2 atmospheres of pressure. Dives were performed on consecutive days.

Over a 5-month healing period, the patient showed no evidence of impaired healing or ORN (Fig 2). Thereafter, planning for implant placement by the use of Nobel Procera software (Nobel Biocare, Zurich, Switzerland) began. Radiographic guides and indexes, reproducing the ideal positioning of the planned restorations, were fabricated by the maxillofacial prosthodontist according to the NobelGuide double-scan protocol (Nobel Biocare).⁹ Per the NobelGuide protocol, by use of the double-scan technique, the patient underwent medical computed tomography scans while wearing the radiographic guides and indexes. The computed tomography images were imported into the Nobel Procera software program, and 9 dental implants were planned "virtually" in the maxilla and mandible (Figs 3, 4). Once completed, the treatment plan was sent via the Internet to Nobel Biocare for fabrication of the surgical guide appliances (NobelGuide) (Fig 5).

Nine months after the extractions, 9 dental implants were placed in a flapless fashion, by use of the appropriate implant-specific instrumentation. Healing abutments were placed at that time (Fig 6). The patient tolerated the procedure well and was then treated with 10 additional HBO dives.

The immediate postoperative course was uneventful. Six months postoperatively, the patient presented for normal follow-up. At that time, there was evidence

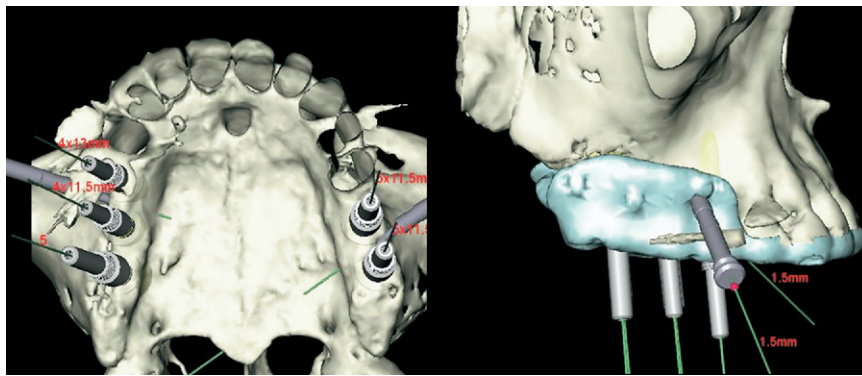


FIGURE 3. Computer-generated virtual treatment plan in maxilla.

Horowitz, Orentlicher, and Goldsmith. Computerized Implantology for Irradiated Patient. J Oral Maxillofac Surg 2009.

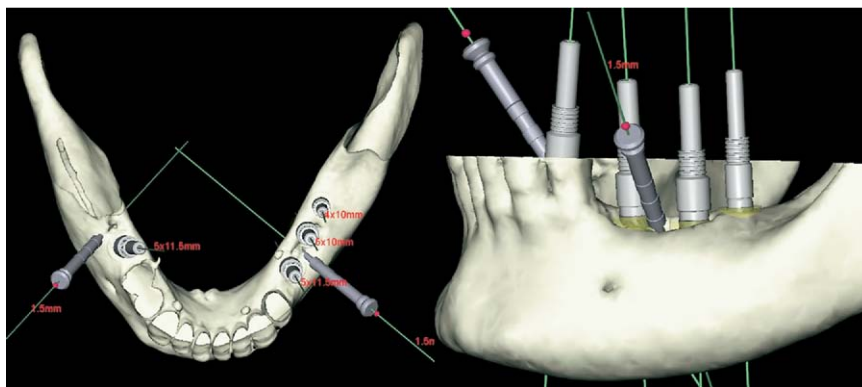


FIGURE 4. Computer-generated virtual treatment plan in mandible.

Horowitz, Orentlicher, and Goldsmith. Computerized Implantology for Irradiated Patient. J Oral Maxillofac Surg 2009.

of implant failure at the site corresponding to the left mandibular second molar. This implant was subsequently removed. After soft tissue healing at the site of the failed implant, the patient returned to the maxillofacial prosthodontist for fabrication of the final prosthesis (Figs 7-12).

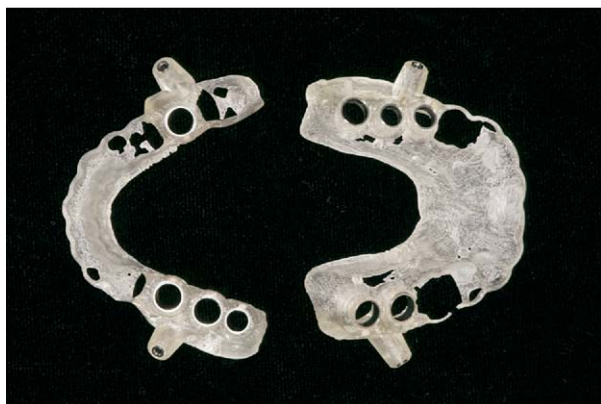

FIGURE 5. Maxillary and mandibular computer-generated surgical guides.

Horowitz, Orentlicher, and Goldsmith. Computerized Implantology for Irradiated Patient. J Oral Maxillofac Surg 2009.

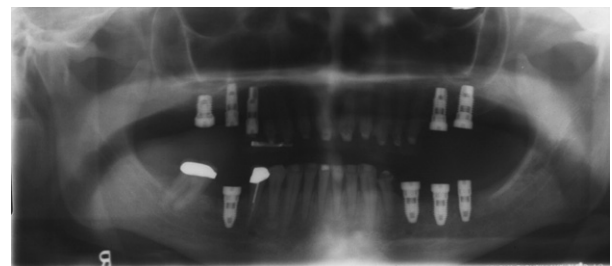


FIGURE 6. Immediate postoperative panoramic radiograph after implant placement.

Horowitz, Orentlicher, and Goldsmith. Computerized Implantology for Irradiated Patient. J Oral Maxillofac Surg 2009.

Currently, more than 2 years after implant placement, the patient has no evidence of further implant failure or other complications.

Discussion

The use of dental implants for tooth replacement is the preferred treatment for many patients. Conventional prosthodontics can be very unpredictable and difficult in head and neck cancer patients. These pa-

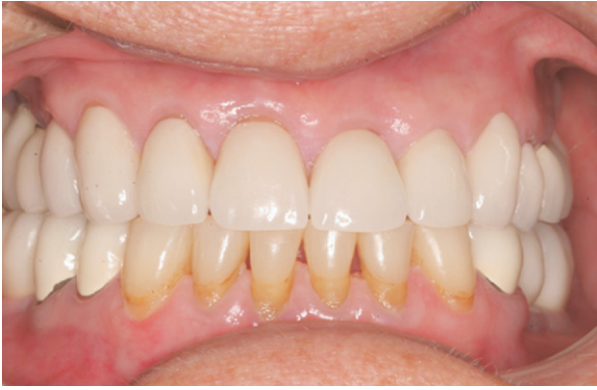

FIGURE 7. Maxillomandibular occlusal relationship of the final prosthesis.

Horowitz, Orentlicher, and Goldsmith. Computerized Implantology for Irradiated Patient. J Oral Maxillofac Surg 2009.

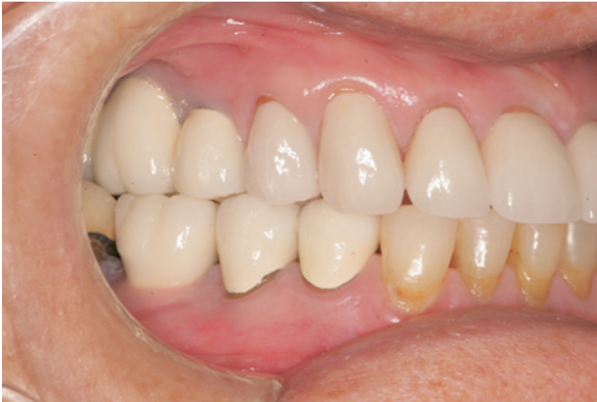

FIGURE 8. Right lateral view. Note excellent appearance of final prosthesis on maxillary right first molar, second premolar, and mandibular right first molar.

Horowitz, Orentlicher, and Goldsmith. Computerized Implantology for Irradiated Patient. J Oral Maxillofac Surg 2009.

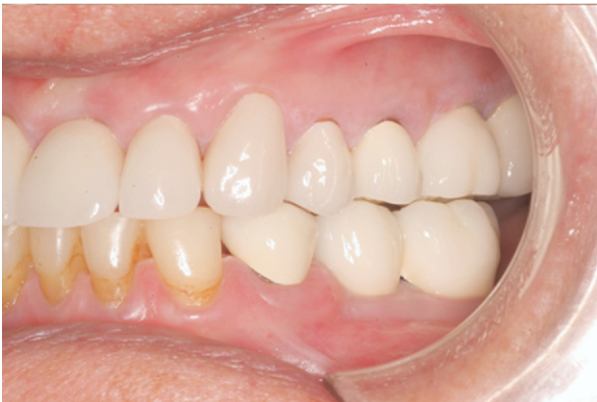

FIGURE 9. Left lateral view of final prosthesis. Note excellent result of permanent crowns placed on the implants corresponding to the left maxillary first and second molars and the left mandibular first molar and second premolar.

Horowitz, Orentlicher, and Goldsmith. Computerized Implantology for Irradiated Patient. J Oral Maxillofac Surg 2009.

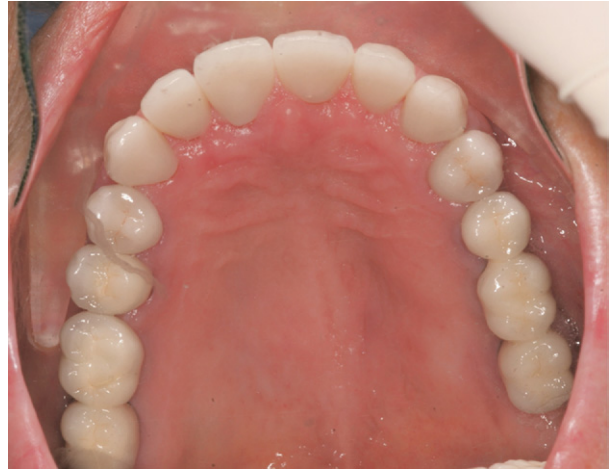

FIGURE 10. Final prosthesis in maxilla.

Horowitz, Orentlicher, and Goldsmith. Computerized Implantology for Irradiated Patient. J Oral Maxillofac Surg 2009.

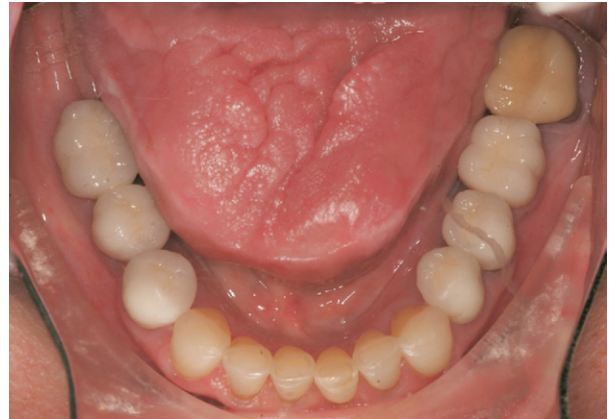

FIGURE 11. Final prosthesis in mandible.

Horowitz, Orentlicher, and Goldsmith. Computerized Implantology for Irradiated Patient. J Oral Maxillofac Surg 2009.

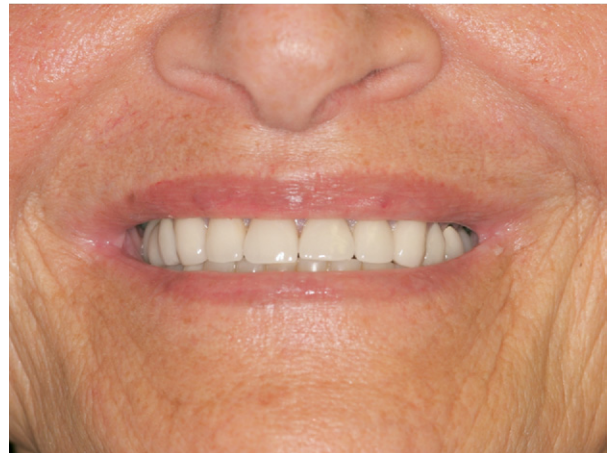

FIGURE 12. Final prosthesis.

Horowitz, Orentlicher, and Goldsmith. Computerized Implantology for Irradiated Patient. J Oral Maxillofac Surg 2009.

tients are often lacking the hard and soft tissue that would otherwise serve as support for dental restorations.¹⁰ If xerostomia is present, the mucosa may not tolerate removable prostheses. The anatomy of the areas requiring restoration is frequently distorted and scarred. Postoperative radiation therapy and the resultant hypovascularity of the bone and soft tissue in the area may leave these patients with a less-than-ideal situation for the placement of dental implants. Surgical procedures performed in irradiated tissues present a major risk for ORN as compared with nonirradiated tissues.¹¹ In addition, the placement of dental implants in these patients was originally considered to be contraindicated.¹²

Today, there still remains no consensus as to how these patients should be managed. Some authors advocate placement of dental implants primarily, at the time of reconstruction,¹³ whereas others advocate delayed placement.¹ In addition, the use of HBO therapy as a requirement before implant placement is a debated topic.^{14,15} Granström reported¹⁶ a study of the placement of 4,392 dental implants that showed an improved survival rate of implants with HBO. The American Association of Oral and Maxillofacial Surgeons outlines HBO as a therapeutic standard for irradiated bone.¹⁷ Although HBO has been successful in improving implant survival rates, it is prudent that the complications of radiation therapy, such as ORN, be minimized.

Minimally invasive surgery has become popular in many areas of medicine and may be applicable in performing reconstruction in the head and neck cancer patient. Sarment et al¹⁸ showed that implants placed using a surgical guide fabricated from a stereolithic model were nearly 2 times more accurate than those placed with a conventional surgical guide. van Steenberghe et al¹⁹ showed that implants can be placed within 0.8 mm of the location of the planned placement. Because of the often distorted anatomy in head and neck cancer patients, computerized implantology can be of great benefit in the reconstruction of these patients.

Computerized implantology allows the surgeon to place dental implants in an accurate, predictable fashion, according to a prosthetically driven treatment plan. It allows the surgeon to visualize the underlying bone and plan the accurate placement of dental implants before implant surgery. It facilitates the accurate placement of implants without reflecting the soft tissue (flapless surgery). Computerized implantology

minimizes the postoperative bleeding and discomfort and, ultimately, the overall surgical trauma.²⁰ Computerized implantology and flapless surgery may decrease the risk of postoperative complications from implant surgery in patients susceptible to ORN.

References

1. McGhee MA, Stern SJ, Callan D, et al: Osseointegrated implants in the head and neck cancer patient. *Head Neck* 19:659, 1997
2. Regezi JA, Courtney RM, Kerr DA: Dental management of patients irradiated for oral cancer. *Cancer* 38:994, 1976
3. Sulaiman F, Huryn J, Zlotolow IM: Dental extractions in the irradiated head and neck patient: A retrospective analysis of Memorial Sloan-Kettering cancer center protocols, criteria, and end results. *J Oral Maxillofac Surg* 61:1123, 2003
4. Mekhail TM, Adelstein DJ, Rybicki LA, et al: Enteral nutrition during the treatment of head and neck carcinoma. *Cancer* 91:1785, 2001
5. Hammerlid E, Wirblad B, Sandin C, et al: Malnutrition and food intake in relation to quality of life in head and neck cancer patients. *Head Neck* 20:540, 1998
6. Eckert SE, Desjardins RP, Keller EE, et al: Endosseous implants in an irradiated tissue bed. *J Prosthet Dent* 76:45, 1996
7. Marx RE: Osteoradionecrosis: A new concept of its pathophysiology. *J Oral Maxillofac Surg* 41:283, 1983
8. Marx RE, Ames JR: The use of hyperbaric oxygen therapy in bony reconstruction of the irradiated and tissue-deficient patient. *J Oral Maxillofac Surg* 40:412, 1982
9. Bedrossian E: Laboratory and prosthetic considerations in computer-guided surgery and immediate loading. *J Oral Maxillofac Surg* 65(Suppl 1):47, 2007
10. Watzinger F, Ewers R, Henninger A, et al: Endosteal implants in the irradiated lower jaw. *J Craniomaxillofac Surg* 24:237, 1996
11. Koga DH, Salvajoli JV, Alves FA: Dental extractions and radiotherapy in head and neck oncology: Review of the literature. *Oral Dis* 14:40, 2008
12. Dental implants. *Natl Inst Health Consens Dev Conf Consens Statement* 7:1, 1988
13. Urken ML, Buchbinder D, Weinberg H, et al: Primary placement of osseointegrated implants in microvascular mandibular reconstruction. *Otolaryngol Head Neck Surg* 101:56, 1989
14. Donoff RB: Treatment of the irradiated patient with dental implants: The case against hyperbaric oxygen treatment. *J Oral Maxillofac Surg* 64:819, 2006
15. Granström G: Placement of dental implants in irradiated bone: The case for using hyperbaric oxygen. *J Oral Maxillofac Surg* 64:812, 2006
16. Granström G: Radiotherapy, osseointegration and hyperbaric oxygen therapy. *Periodontol* 2000 33:245, 2003
17. Parameters of care: Clinical practice guidelines for oral and maxillofacial surgery, version 4.0. *J Oral Maxillofac Surg* (Suppl):IMP-18, 2007
18. Sarment DP, Sukovic P, Clinthorne N: Accuracy of implant placement with a stereolithic surgical guide. *Int J Oral Maxillofac Implants* 18:571, 2003
19. van Steenberghe D, Naert I, Andersson M, et al: A custom template and definitive prosthesis allowing immediate implant loading in the maxilla: A clinical report. *Int J Oral Maxillofac Implants* 17:663, 2002
20. Becker W, Goldstein M, Becker B, et al: Minimally invasive flapless implant surgery: A prospective multicenter study. *Clin Implant Dent Relat Res* 7(Suppl 1):S21, 2005